

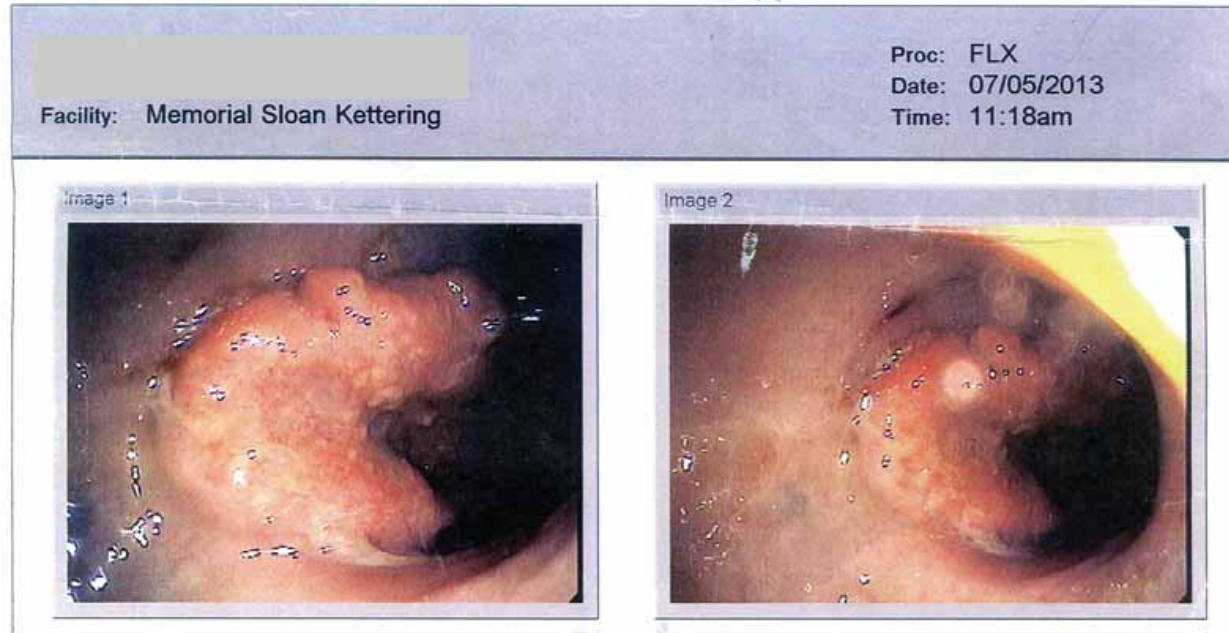
Case report: Colon cancer

- 51 year old male, colon cancer stage 2
- Non-smoker, non-drinker, not on medications
- Past medical history of ulcerative colitis since age 18
- Diagnosed 30-May-2013 - Colonoscope found sigmoid mass between 27-37 cm
- Was advised to have surgery to remove whole colon, radiation & chemotherapy, but refused
- Aug 2013 started treatments
 - Vegetarian diet, vegetable juices, no sugar, Modified citrus pectin (MCP), Poly-MVA, Enzymes
 - 1200 mg Curcumin/Turmeric, 1-2 times/day with meals
 - Vitamin D 5000 IU daily
- Nov 2014 started initial Ozone therapy treatments

Case report: Colon cancer

- 21-Nov-2013 patient contacted Saisei Mirai Clinics
- Dec 2013 started 0.5 ml GcMAF (1500 ng/0.5 ml), 2 times/wk IM/SC injection. 104 doses until Dec 2014. Continuing GcMAF
- Jan 2014 Ozone therapy - daily for 3 weeks, then 2 times/wk for 6 months, followed by 1 time/wk
- Tumor marker CEA (normal 0.0-4.0 µg/l)
 - 21-Jul-2014 6.2 µg/l
 - 2-Oct-2014 5.6 µg/l
- Weight loss due to new diet and feeling much better
 - 30-May-2014 - 102 kg
 - 20-Oct-2014 - 82 kg

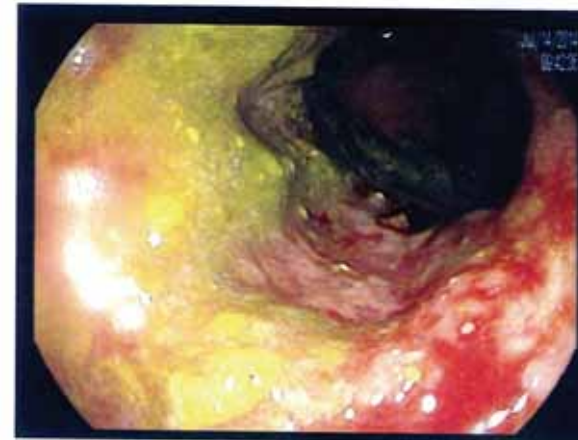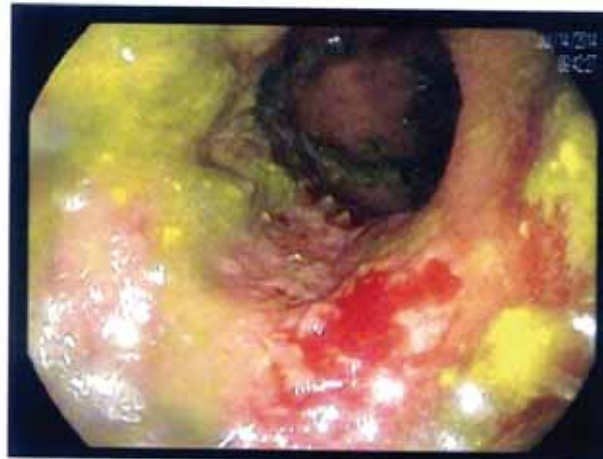
Case report: Colon cancer



5-Jul-2013

14-Jul-2014

Shrinkage
from 2013



Flexible sigmoidoscopy examination